

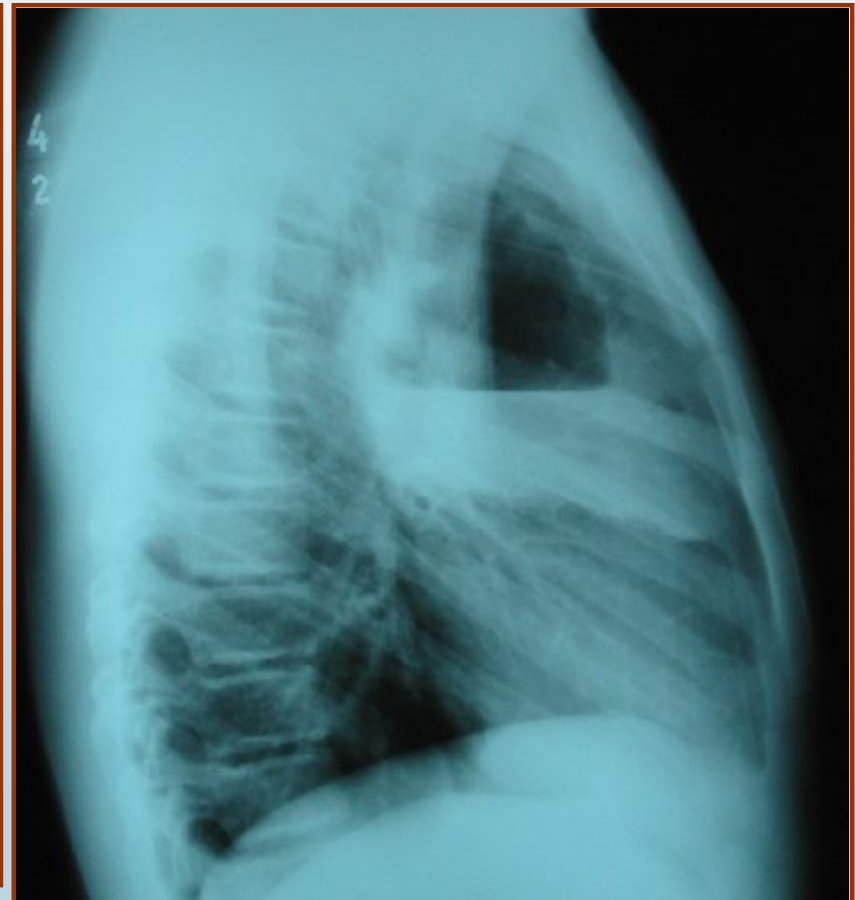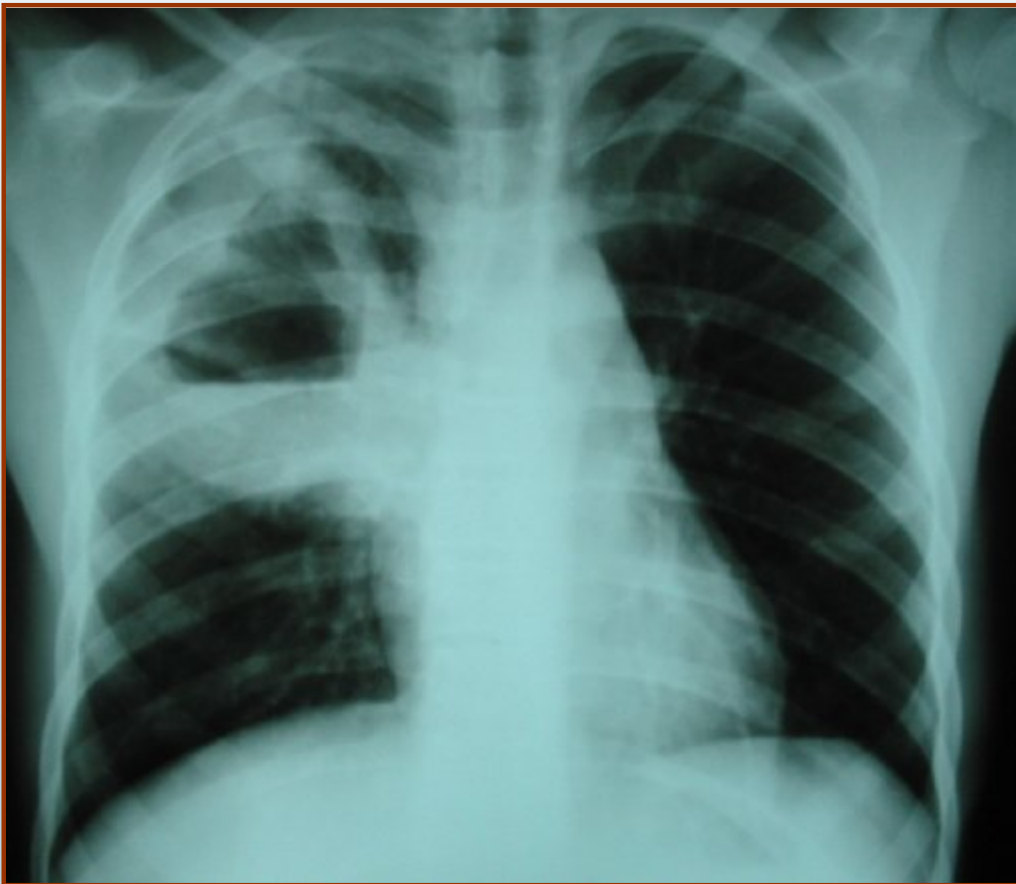
CASOS DA SEMANA

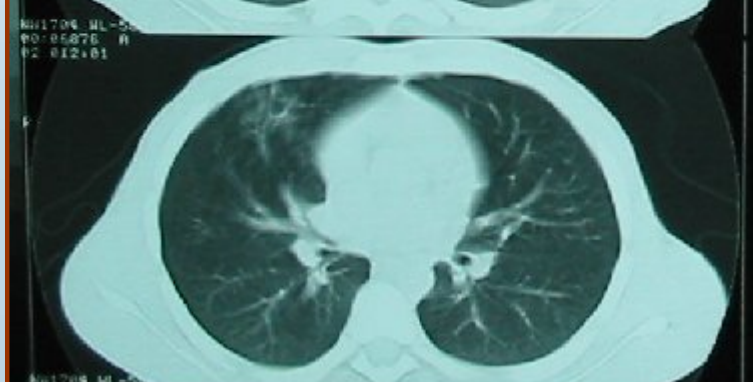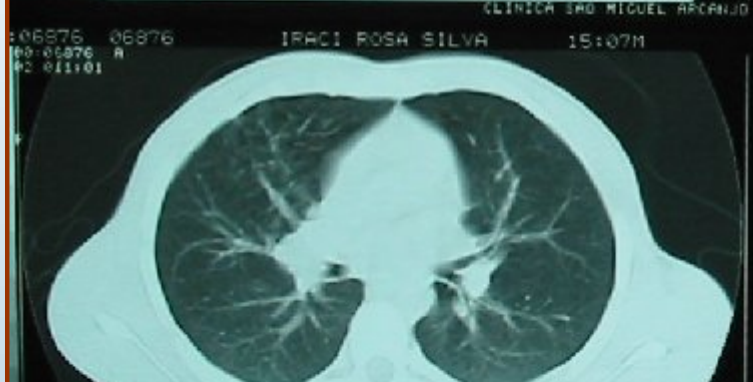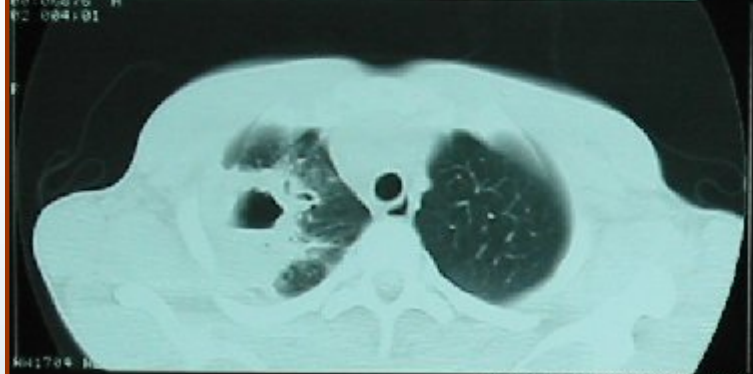
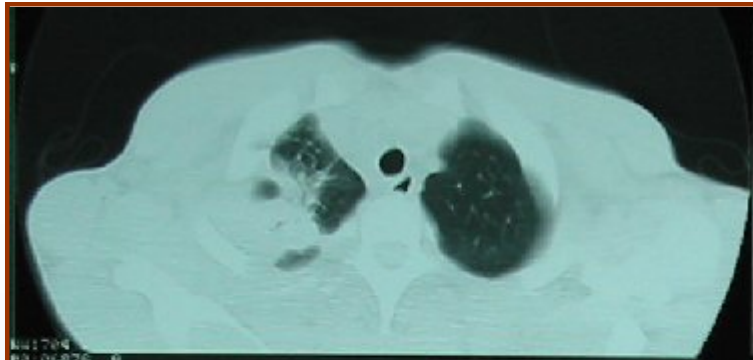
HINSG

CASO N.1

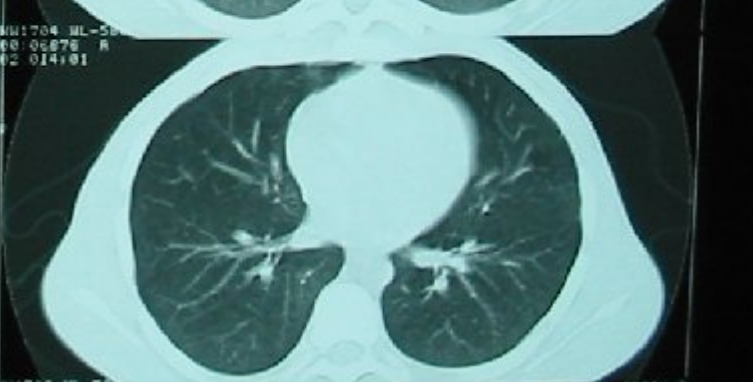
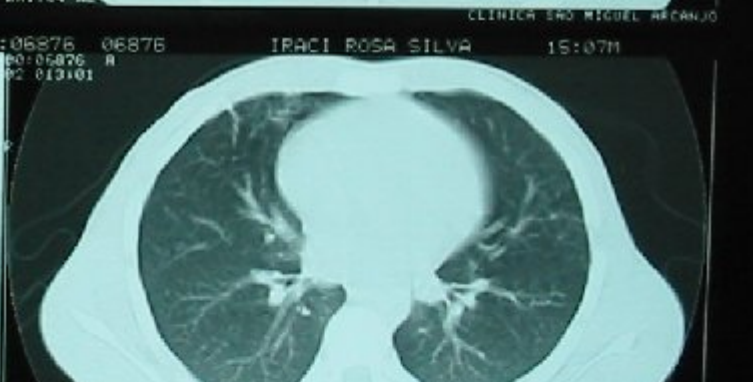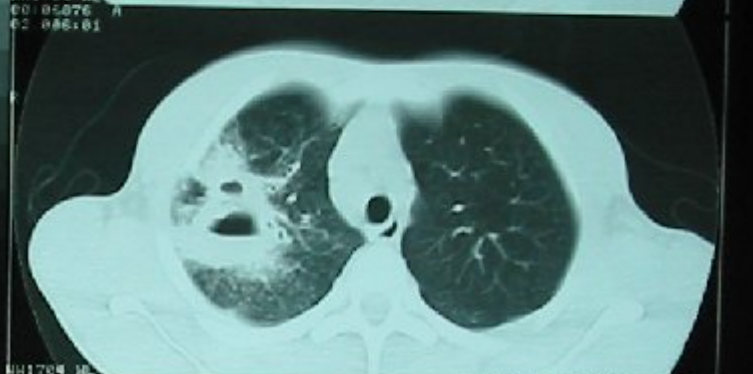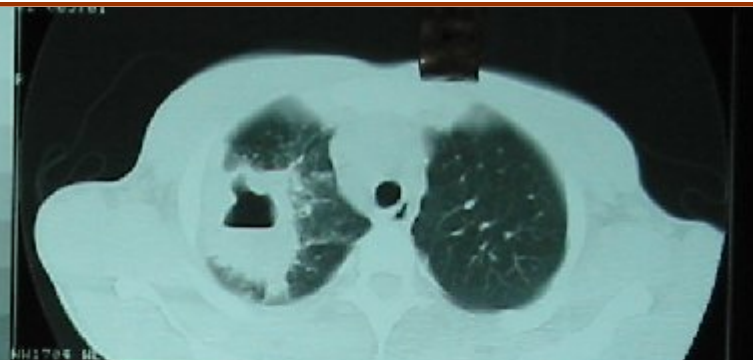
MASC 14 A

TOSSE COM EXPECTORAÇÃO, FEBRE 39.2 GRAUS
ADINAMIA E PROSTRAÇÃO





CLINICA DRº MIGUEL ARCANJO
IRACI ROSA SILVA 15:07M



CLINICA DRº MIGUEL ARCANJO
IRACI ROSA SILVA 15:07M

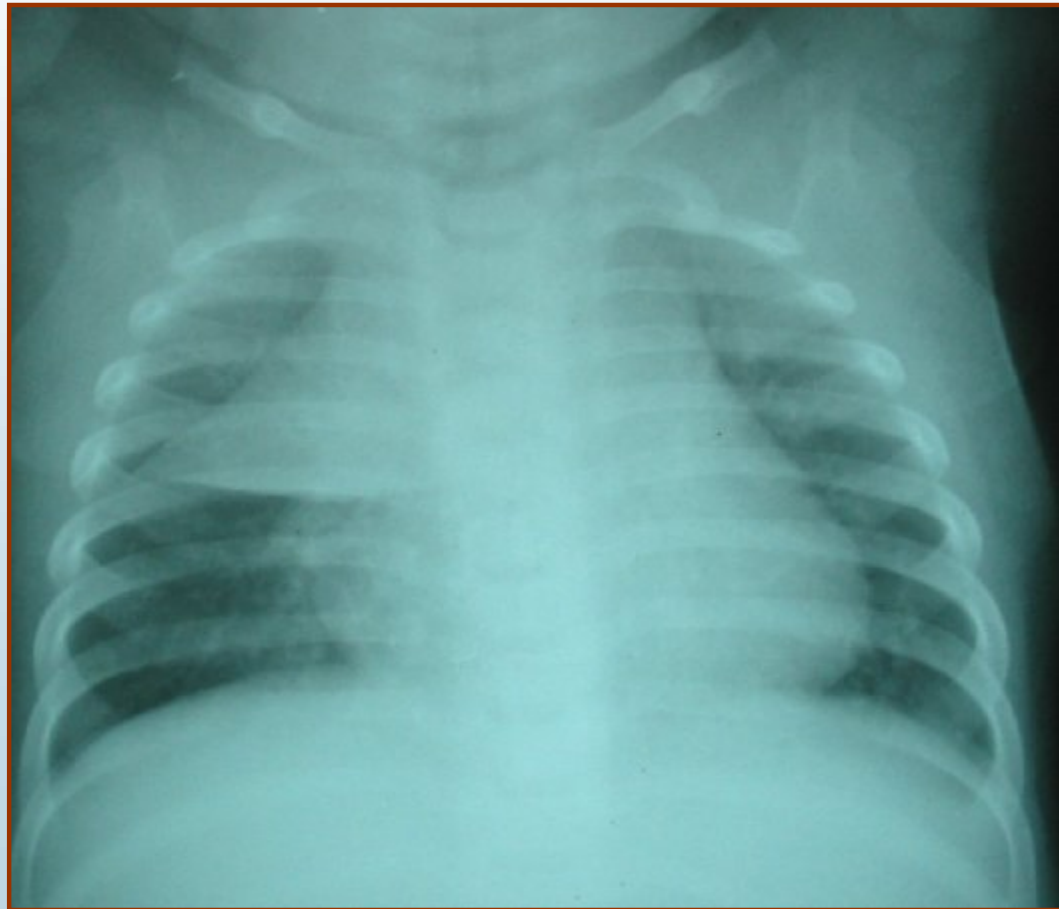CITE OS SINAIS
RADIOLÓGICOS DESTA LESÃO!

DIAGNÓSTICO ?

CASO N.2

MASC 2 A $\frac{1}{2}$

FEBRE BAIXA NÃO TERMOMETRADA



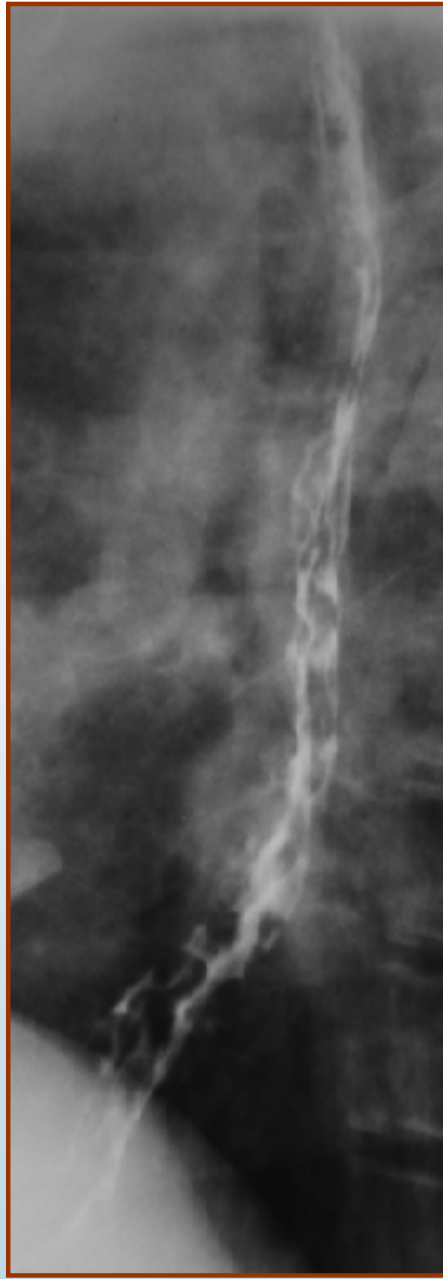
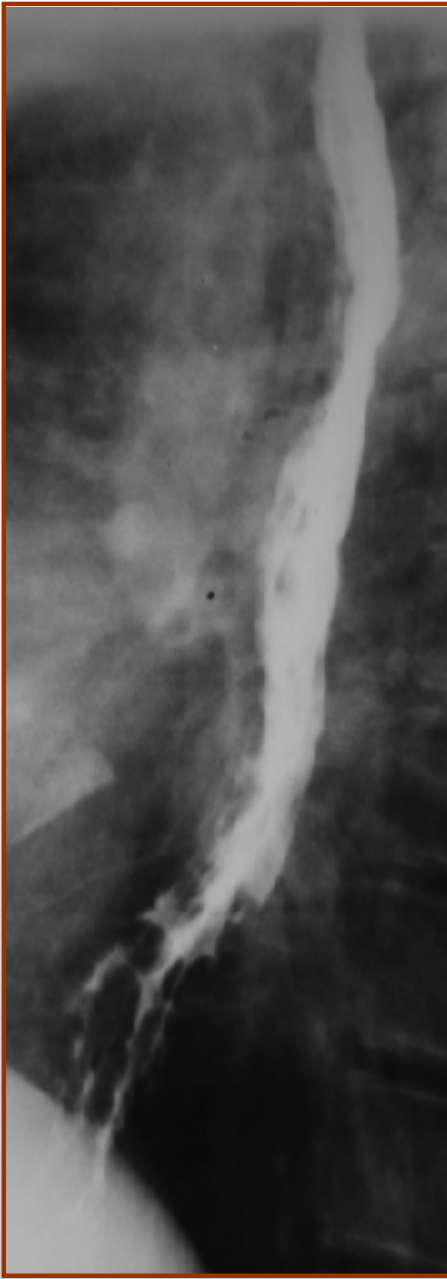
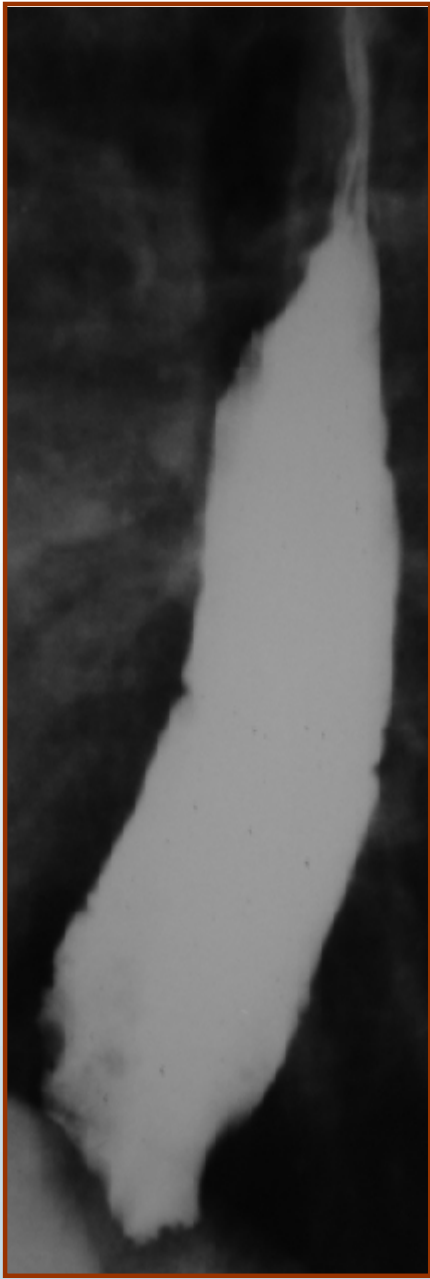
**DESCREVA A IMAGEM
RADILÓGICA!**

CITE 1 SÓ DIAGNÓSTICO!!!

CASO N.3

11 A HEMATÊMESE

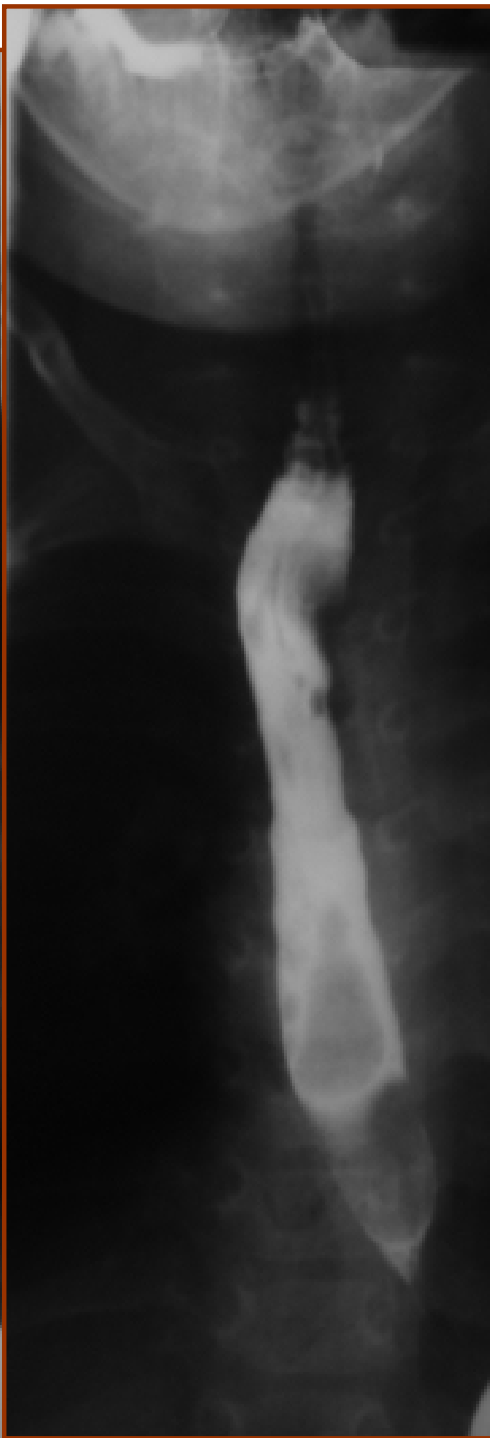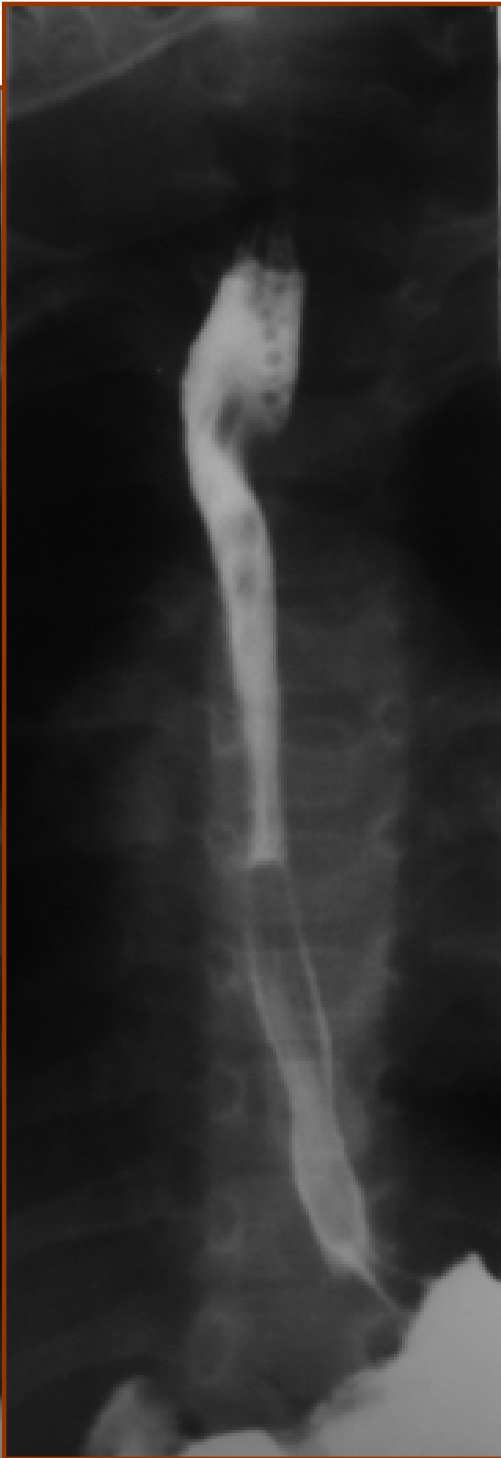
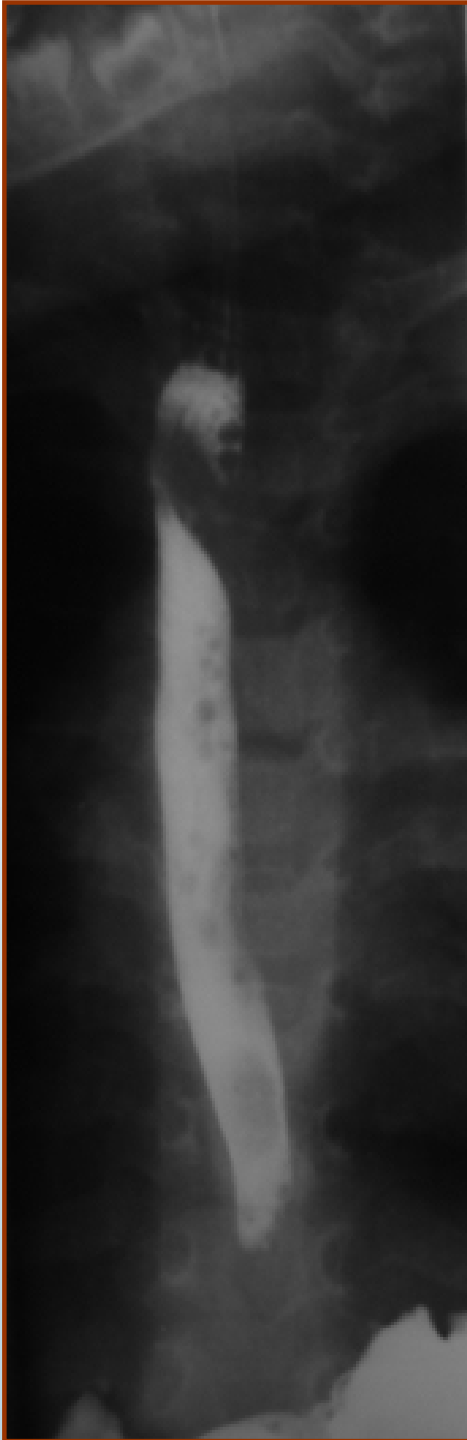QUAIS OS SINAIS
RADIOLÓGICOS VISIBILIZADOS
NESTA LESÃO ???

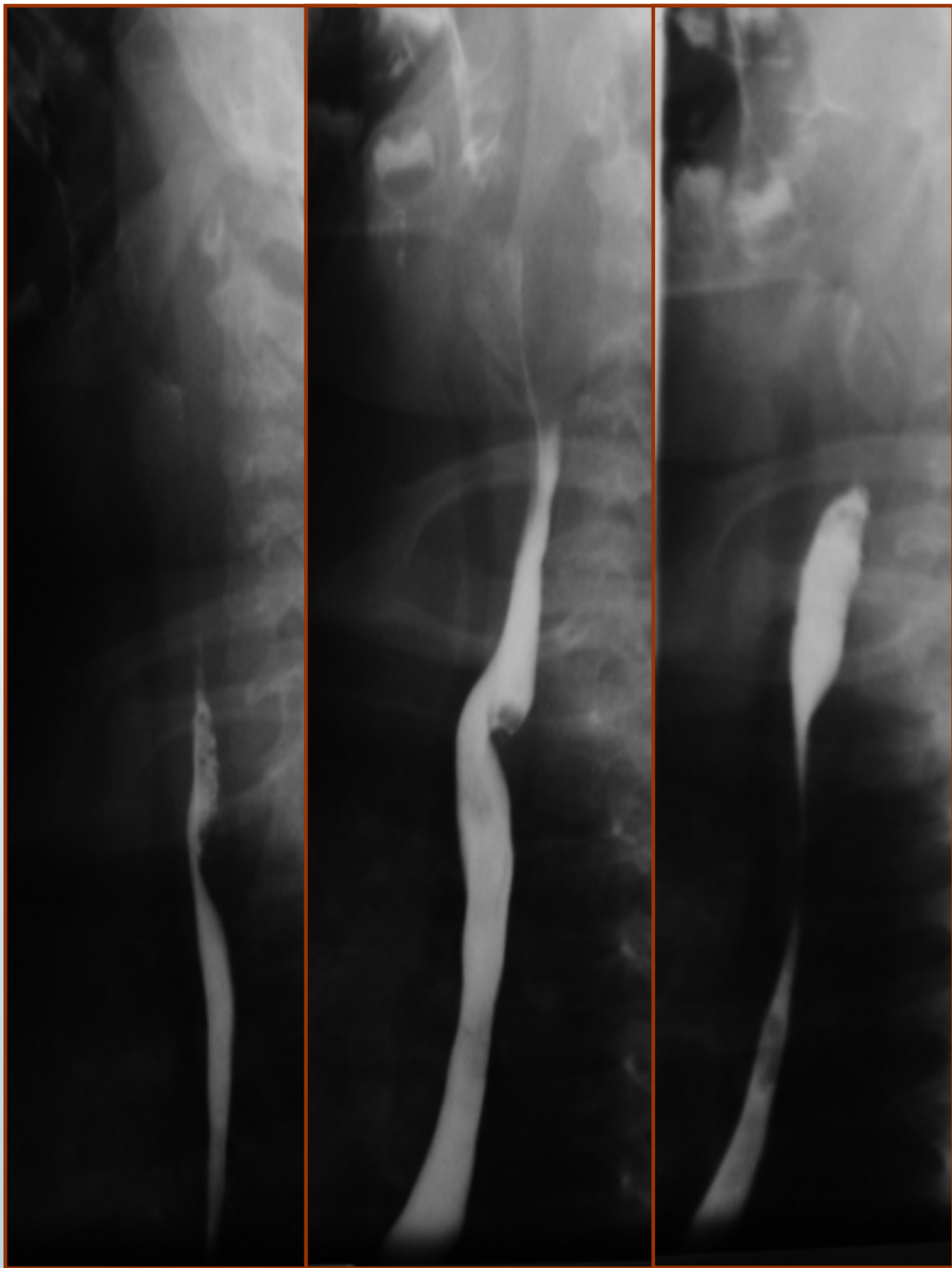

DIAGNÓSTICO ?????

CASO N.4

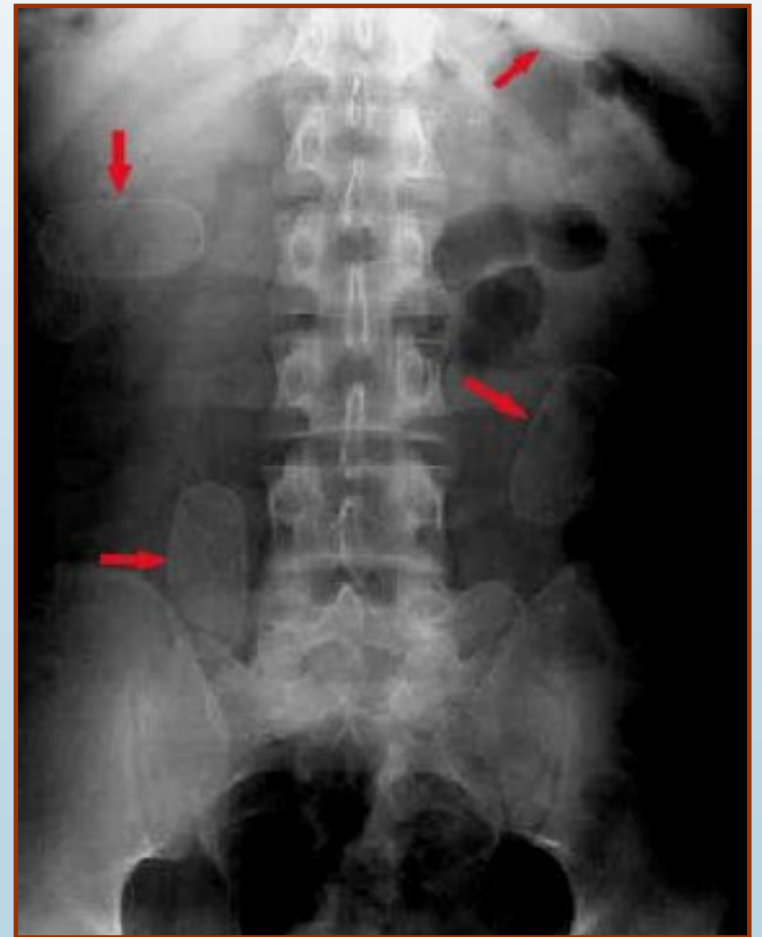
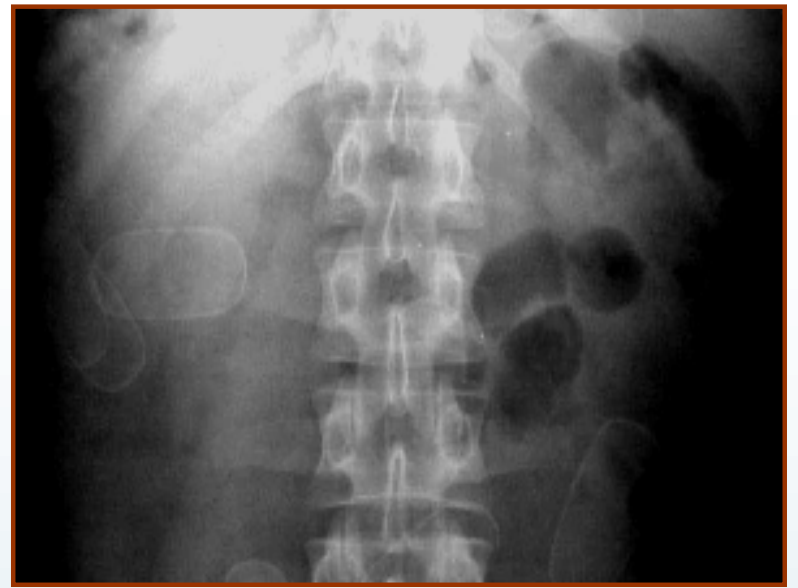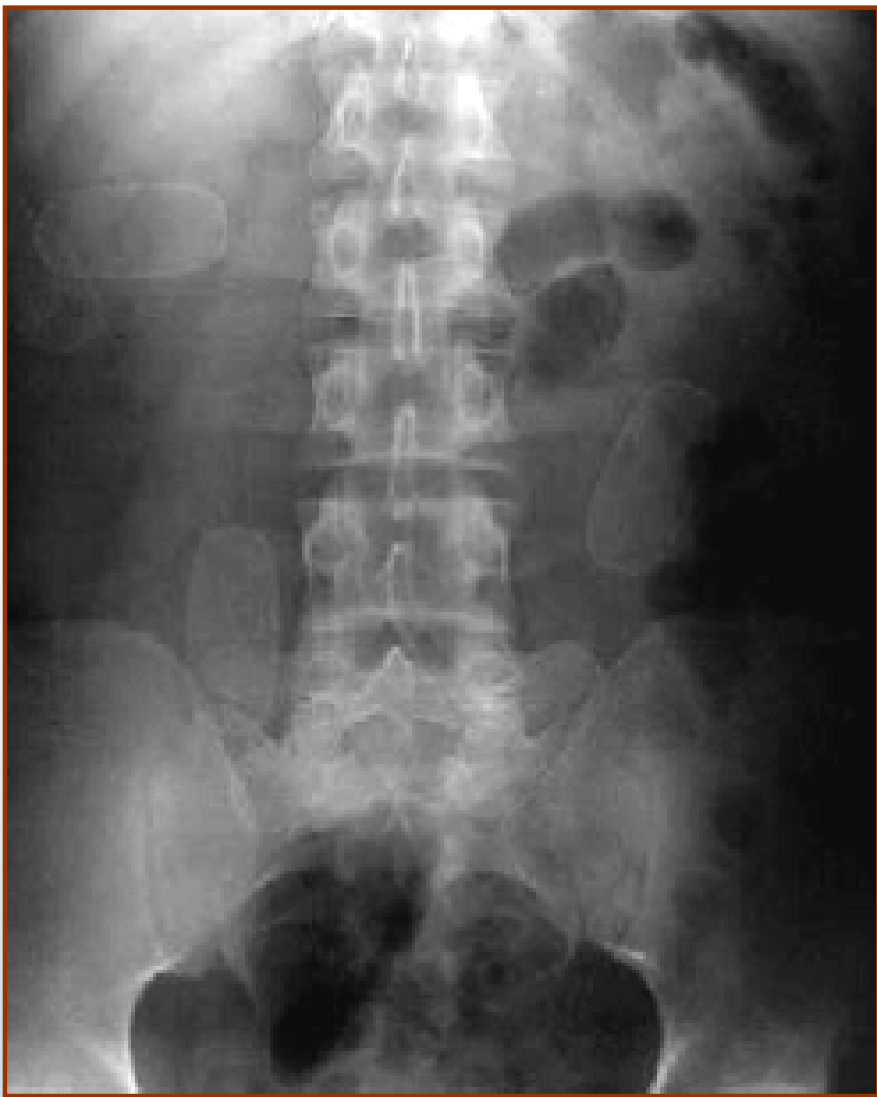VEIO AO HINSG PRÁ PESQUISA DE RGE.





DIAGNÓSTICO ???

VC JÁ VIU CASO IGUAL A ESTE??????



DIAGNÓSTICO ???